

# Tissue-Engineered Augmentation of a Rotator Cuff Tendon Using a Novel Reinforced Implant: A Preliminary Study In Sheep

William R Walsh PhD<sup>1</sup>, Andrew J Carter PhD<sup>2</sup>, Vedran Lovric PhD<sup>1</sup>, James Crowley BVSc<sup>1</sup>, Dan Wills BVSc<sup>1</sup>, Tian Wang PhD<sup>1</sup>, Gregory Kanski MD<sup>3</sup>, Robert Stanton MD<sup>4</sup>, Steven Arnoczky DVM<sup>5</sup>, Robert Arciero MD<sup>3</sup>

<sup>1</sup>Prince of Wales Hospital, Sydney, Australia, <sup>2</sup>Accent Biomedical, Stow, MA, <sup>3</sup>Univ of CT Health Center, Southington, CT, <sup>4</sup>Orthopaedic Specialty Group PC, Fairfield, CT, <sup>5</sup>Michigan State University, East Lansing, MI

**Disclosures:** William R Walsh (4–Biorez), Andrew J Carter (3B–Biorez), Vedran Lovric (N), James Crowley (N), Dan Wills (N), Tian Wang (N), Gregory Kanski (N), Robert Stanton (4–Biorez), Steven Arnoczky (4–Biorez), Robert Arciero (4–Biorez)

## Introduction

Surgical repair of torn rotator cuff tendons has been associated with a high degree of re-tears. Recent studies have shown that augmenting the repair through the induction of new host tissue can prevent gapping or re-tears by increasing the thickness of the tendon. This study investigated the ability of a novel, reinforced (high porosity collagen with PLLA microfilaments) implant to support the rapid proliferation, maturation, and remodeling of new host tissue in an animal model of rotator cuff tendon repair. The reinforced implant was hypothesized to rapidly increase the thickness of the repaired tendon through the addition of functional host tissue.

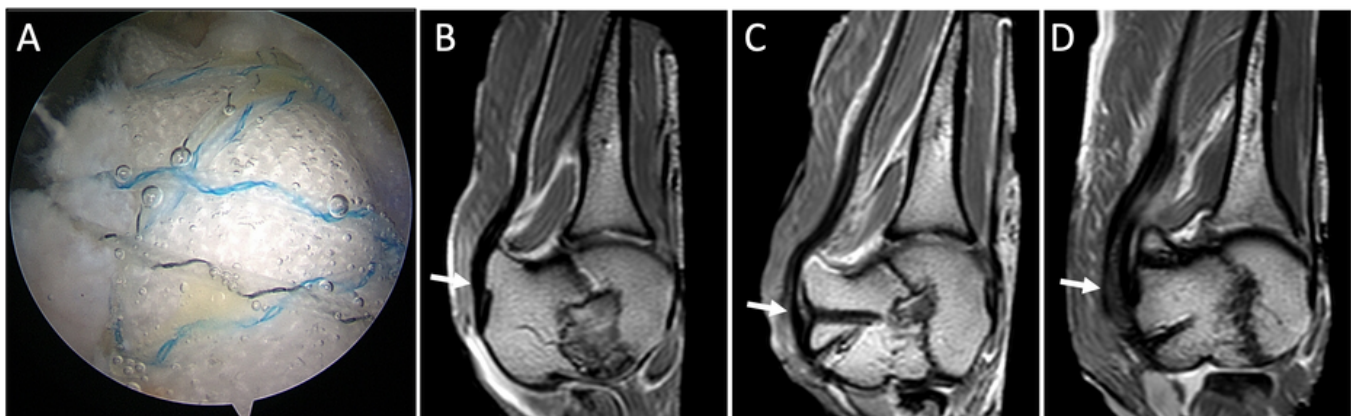
## Methods

The porosity of the reinforced (collagen-PLLA) implant (BioBrace<sup>®</sup>, CONMED) was measured using mercury porosimetry.

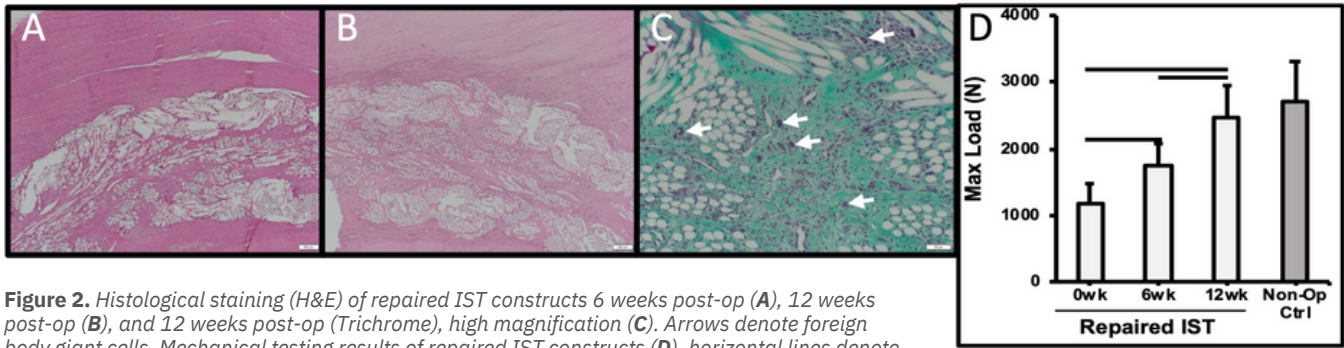
Arthroscopic surgical technique of an augmented rotator cuff repair was evaluated using human cadaveric shoulders. Following Institutional Animal Care and Use Committee approval, a mid-portion detachment of the infraspinatus tendon (IST) was created and repaired in 18 sheep using a double row suture bridge, and augmented using the reinforced implant, mimicking human cadaveric technique. Nine animals were humanely euthanized at either 6 or 12 weeks for radiography, micro-computed tomography, MRI, histology, or biomechanical testing.

## Results

**Mercury Porosimetry:** The reinforced implant had an average porosity of 80%, median pore diameter of 19.4 micron, and pore volume of 4.2 cm<sup>3</sup>/gram. **Surgical Technique:** The BioBrace<sup>®</sup> could be introduced into the joint arthroscopically and incorporated using a double row suture bridge (**Fig. 1A**). **Imaging (T2 MRI):** The mean thickness in the IST (**Fig. 1B** arrow) of non-operated animals was 3.5 mm while the mean thickness of the repaired ISTs was 10.0 mm at six weeks and 9.8 mm at twelve weeks (**Fig. 1C/D**). **Histology:** At six weeks the BioBrace<sup>®</sup> was infiltrated by host fibroblasts and fibrovascular tissue. Dense, regularly oriented connective tissue was also observed on the superior and inferior surfaces of the BioBrace<sup>®</sup> which added to the overall thickness of the healing tendon (**Fig. 2A**). By 12 weeks there was maturation and remodeling of the fibrovascular connective tissue within the BioBrace<sup>®</sup> as well as on its inferior and superior surfaces (**Fig. 2B**). Scattered foreign body giant cells (arrows) were observed at both 6 and 12 weeks and were associated with the PLLA fibers (**Fig. 2C**). **Mechanical testing:** The ultimate tensile strength (UTS) of the repaired IST construct significantly increased between 0 (1163 ± 303N) and 6 weeks (1740 ± 338N) (p=0.01), and 6 (1740 ± 338N) and 12 weeks (2463 ± 484N) (p=0.01) (**Fig. 2D**). There was no significant



**Figure 1.** Arthroscopic image of augmented repair (A), T2 MRI imaging of ISTs (arrows) on non-operated (B), 6 weeks post-op (C), 12 weeks post-op (D).



**Figure 2.** Histological staining (H&E) of repaired IST constructs 6 weeks post-op (A), 12 weeks post-op (B), and 12 weeks post-op (Trichrome), high magnification (C). Arrows denote foreign body giant cells. Mechanical testing results of repaired IST constructs (D), horizontal lines denote significance ( $p < .05$ )

difference in UTS between repaired ( $2463 \pm 484N$ ) and contralateral control tendons ( $2707 \pm 605N$ ) at 12 weeks ( $p=0.35$ ) (**Fig. 2D**).

### Discussion

The collagen-PLLA reinforced implant increased the thickness of a repaired rotator cuff tendon through the rapid induction of host-generated dense, regularly-oriented connective tissue. The new host tissue demonstrated functional remodeling over time resulting in a repair that was as strong as the unoperated control by 12 weeks.

### Significance/Clinical Relevance

Healing of rotator cuff repairs has been a challenging clinical problem. In addition, functional outcomes are improved with integrity of the rotator cuff after repair. This study shows that a reinforced implant induced a proliferative healing response that improved the thickness of the repair tissue, and was as strong as controls. This has strong potential as an adjunct for rotator cuff repair.

**This abstract or variations thereof was presented at the following conferences:** Rocco et al. Biologic Scaffolds for Regenerative Medicine 11th Symposium

2021 (Podium)

Kanski et al. OSET 2020 (Podium, Awarded Best Science Paper)

Walsh et al. ORS 2021 (Podium)

Carter et al. AAOS 2021 (Accepted, Poster)

Rocco et al. Military Health System Research Symposium 2021 (Accepted, Poster)

[www.CONMED.com](http://www.CONMED.com)

BBST03\_0721A

©2024 CONMED Corporation, 1363575377 5/24

**BioBrace**