

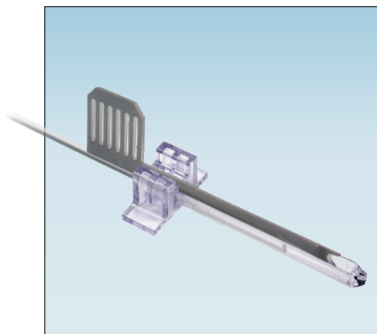


## CASE STUDY

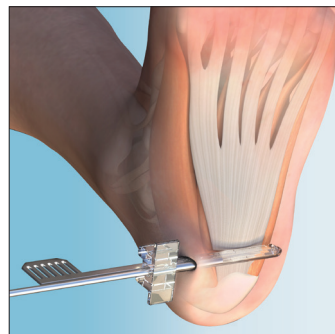
# ClearGuard LE™ System for Endoscopic Plantar Fascia Release



David Millward, DPM, FACFAS



**ClearGuard LE™**  
Endoscopic Soft Tissue Release System



Plantar Fascia Release



A GLOBAL EXTREMITY COMPANY

# ClearGuard LE™ System for Endoscopic Plantar Fascia Release

Author: David Millward DPM FACFAS

Figure 1

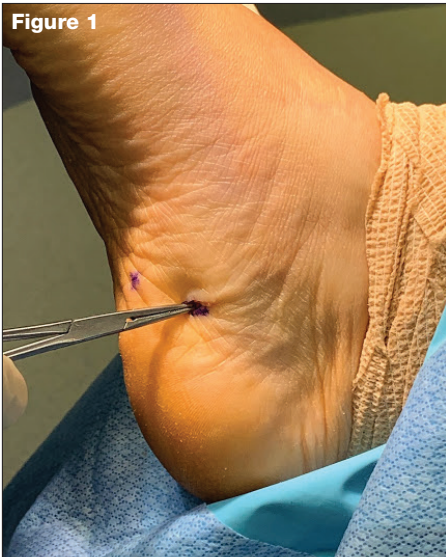

Figure 2

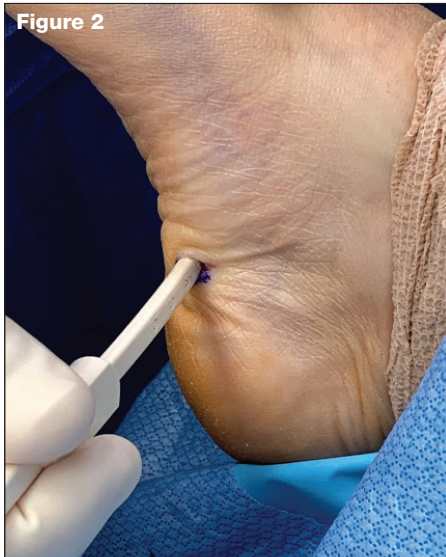
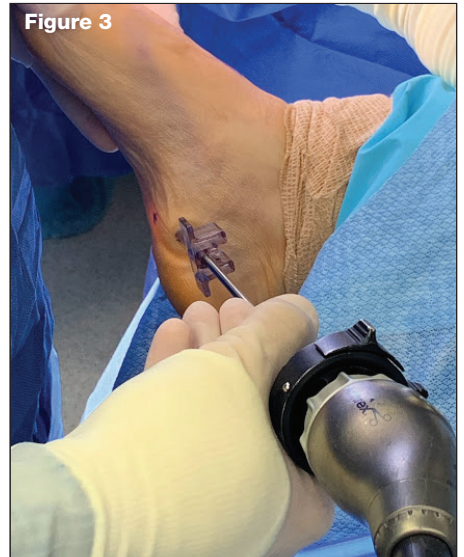
Figure 3



## Introduction

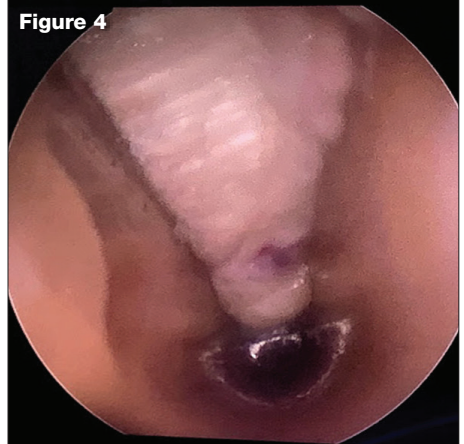
A 43-year-old female presented with a long-standing history of heel pain. She complained of pain to the right heel near the medial plantar tubercle. It had been present for several years. She related most pain to the first few steps in the morning and getting up after rest. She said that she had been doing daily stretching, wearing orthotics, night splints, has tried Nsaids, and had multiple injections in the past. These activities helped for short durations of time but it continued to get worse and she decided to pursue surgical correction. On exam, she had pain with palpation to the plantar medial tubercle and a negative tarsal tunnel exam. She had a tight plantar fascial ligament which was increased with dorsiflexion of the digits, and mild gastroc equinus deformity to the right lower extremity. After three injections over a year period, the recommendation was made to perform an endoscopic plantar fascial release.

## Procedure

The patient was brought to the operating room and placed on the operating table in supine position. Anesthesia was then administered. The foot was scrubbed, prepped and draped in the usual aseptic manner. It was then exsanguinated with an Esmarch bandage and tourniquet was inflated.

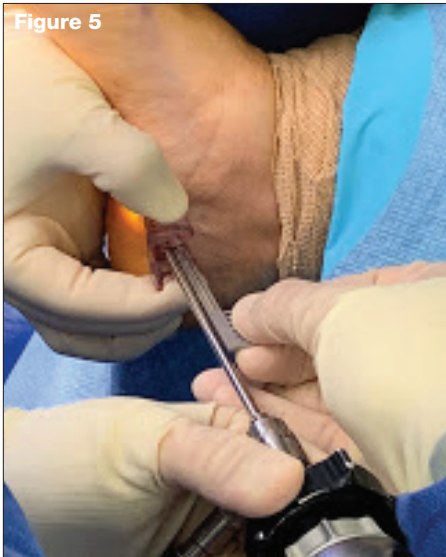
Attention was directed to the patient's medial right heel, where the medial calcaneal tubercle was palpated. A vertical 1cm incision was made approximately 1cm distal from the medial calcaneal tubercle. The incision was deepened into the subcutaneous tissues using blunt dissection. A straight hemostat was inserted and utilized to identify the boundaries of the plantar fascia, and was used to bluntly dissect the surrounding tissue from the plantar fascial ligament. **(Figure 1)** Puckering was noted to the plantar aspect of the patient's left foot, confirming proper placement of the ClearGuard LE™ elevator. Using the ClearGuard LE™ elevator the surrounding soft tissue was

Figure 4

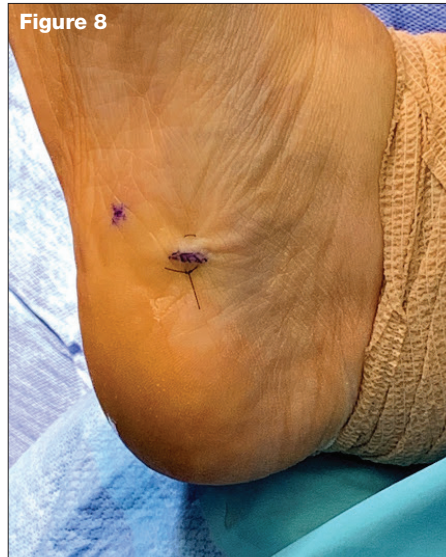

freed from the plantar fascial ligament. The ClearGuard LE™ Rasp was then inserted and the plantar fascial ligament was rasped to remove any remaining tissue from the plantar fascial ligament. **(Figure 2)** Next, the ClearGuard LE™ cannula was inserted into the incision site, Q-tips were used to remove any fatty deposits or other debris. The scope was then placed through the cannula to visualize the plantar fascia. **(Figure 3 and 4)** Once excellent visualization was achieved, the blade was inserted into the cannula superior to the scope. **(Figure 5)** The blade was advanced laterally under direct visualization using the

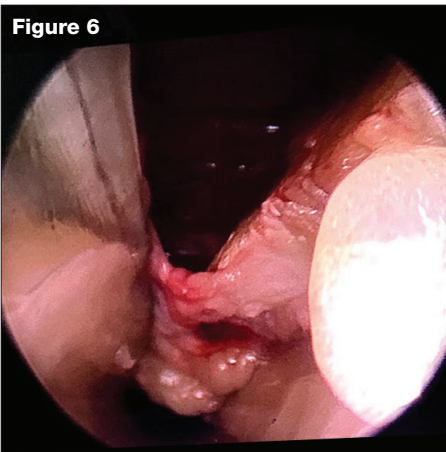




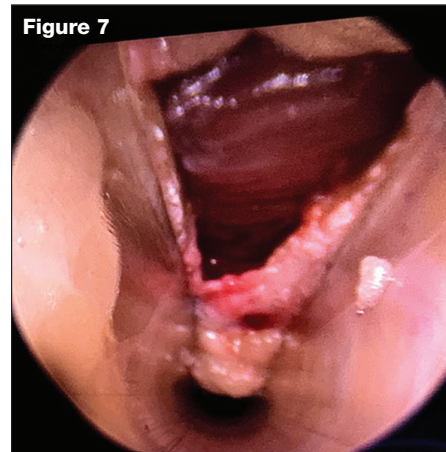
**Figure 5**



**Figure 8**



**Figure 6**



**Figure 7**

scope, and excellent release of the medial band of the plantar fascia was noted with visualization of the underlying FBD muscle belly. **(Figure 6)** Under endoscopic evaluation, it was also noted that the lateral band of the plantar fascia was intact while the medial band of the plantar fascia was appropriately released. **(Figure 7)** With the cannula in place, once again Q-tips were used to remove any remnants of fat. The surgical site was then flushed with copious amounts of normal sterile saline.

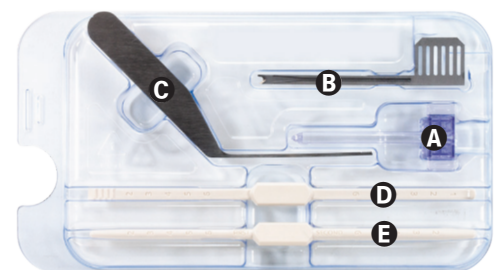
The medial incision site was approximated and coapted utilizing 4-0 nylon in a horizontal mattress technique.

**(Figure 8)** The incision site was then anesthetized using 10cc of 0.5% Marcaine plain. The surgical site was dressed with adaptic, 4 x 4s, Kling roll, 4 inch Ace bandage. Once stable the patient was discharged to home with a cam boot.

### Discussion

I have been doing endoscopic plantar fascial releases for the past 9 years. I have used a variety of systems from a variety of companies over the years. The ClearGuard LE™ has improved upon past systems shortcomings. It allows for a uniport incision, with 360-degree

visualization due to the clear cannula, and provides a safer and more predictable outcome with a hard stop at the end of the cannula. The clear cannula houses both the scope and blade, which allows the surgeon better control and direct visualization of the ligament being incised. Due to the uniport design, the patient is able to heal the incision with fewer complications, less scarring, and faster time to recovery. The single-use pre sterile packed instrumentation gives me comfort in knowing I am providing the safest care for my patients. The ClearGuard LE™ soft tissue release system is versatile, easy to use, and can be used in a variety of other soft tissue releases of the foot and ankle.



ClearGuard LE™ Single Use, Sterile Delivery Instrument Tray: **A.** ClearGuard LE Cannula, **B.** Forward Cutting Blade, **C.** In-situ Rasp, **D.** Synovial Elevator/Rasp, **E.** Sequential Dilators



A GLOBAL EXTREMITY COMPANY