

# SUMMARY OF PEER-REVIEWED LITERATURE

## A Prospective, Randomized Evaluation of Acellular Human Dermal Matrix Augmentation for Arthroscopic Rotator Cuff Repair

Barber FA, Burns JP, Deutsch A, Labbé MR, Litchfield RB. *Arthroscopy* 2012;28:8-15.

### Overview

A significant percentage of rotator cuff tears fail to completely heal due to the degenerative nature of the tendon or tension on the repaired tendon. There is no uniformly accepted surgical solution to this problem because even the most advanced biomechanical constructs have been unable to improve the biologically compromised environment.

### Purpose

The purpose of this study was to prospectively evaluate the safety and effectiveness of acellular human dermal matrix augmentation of large rotator cuff tear repairs compared to rotator cuff repair alone.

### Methods

Forty-two patients with large (>3cm) two-tendon rotator cuff tears underwent rotator cuff repair with and without augmentation. Revisions and massive tears over 5cm were excluded. There were 22 patients randomized to the augmentation group and 20 patients randomized to nonaugmented group. Mean clinical follow-up was 24 months and MRI evaluation was obtained at a mean of 14.5 months.

### Results

MRI results showed intact cuffs in 17 of 20 (85%) in the augmented group and 6 of 15 (40%) in the nonaugmented group ( $P < 0.01$ ), as shown in Graph 1. Clinical outcome scores are listed in Table 1.

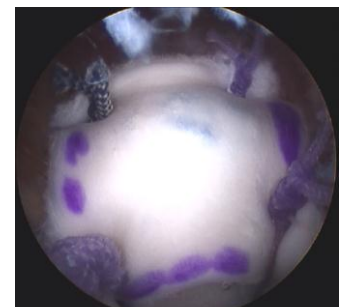


Figure 1: Rotator cuff repair augmented with acellular human dermal allograft.

Table 1: Clinical Outcome Scores

Variable	Augmented (n=22)		Nonaugmented (n=20)		P value
	Preoperative	Postoperative	Preoperative	Postoperative	
ASES score	48.5	98.9	46.0	94.8	0.035
Constant score	41.0	91.9	45.8	85.3	0.008
UCLA score	13.3	28.2	15.9	28.3	0.43

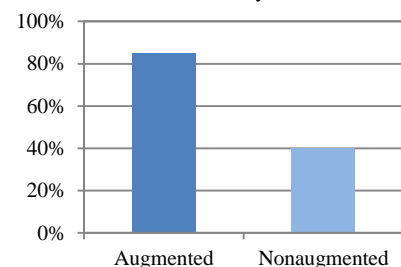
### Discussion

Although most patients improve clinically after cuff repair and show good or excellent clinical outcomes, these may deteriorate long-term because of the presence of retears or of repaired defects that never healed. Rotator cuff tears can increase in size over time and become associated with muscle atrophy and fatty infiltration if not successfully repaired.<sup>1,2</sup>

### Conclusions

Acellular human dermis augmentation of large cuff tears showed better ASES and Constant scores. Intact repairs were detected by MRI in 85% of the augmented group and 40% of the nonaugmented group ( $P < 0.01$ ).

Graph 1: Percent of intact cuffs as detected by MRI



### References

1. Duralde XA, Bair B. Massive rotator cuff tears: The result of partial rotator cuff repair. *J Shoulder Elbow Surg* 2005;14:121-127.
2. Nho SJ, Yadav H, Shindle MK, Macgillivray JD. Rotator cuff degeneration: Etiology and pathogenesis. *Am J Sports Med* 2008;36:987-993.